POOR LEGIBILITY

ONE OR MORE PAGES IN THIS DOCUMENT ARE DIFFICULT TO READ
DUE TO THE QUALITY OF THE ORIGINAL

Consultants in Veterinary Pathology, Inc.
P.O. Box 68 Murrysville, PA 15668-0068
Phone: (724) 733-5154 **Fax:** (724) 733-3032 **E-mail:** vetpathol@cs.com

Fax

To:	Annie Jarabek	**From:**	Bob Garman
Fax:	919-541-1818	**Pages:**	3
Phone:	919-541-4847	**Date:**	77/17/2001
Re:	Perchlorate Study	**CC:**	

☐ **Urgent** x **For Review** ☐ **Please Comment** ☐ **Please Reply** ☐ **Please Recycle**

● **Comments:** Annie, I have appended two topographs. One shows the anatomic landmarks on the ventral and dorsal surfaces of the brain that we use for making our slices. The other is a sagittal view showing the orientation of the three slices from which we take our morphometric measurements. Please note that, even though the same landmarks are used for the PND 10 and PND 22 brains, the sections at these two ages do not look at all alike. For example, we decided to have the anterior commissure present in each Level 1 section. On the PND 22 rats, this section does not include the hippocampus, but the hippocampus is frequently present at this level in the PND 10 brains. This is due to the fact that the brain is rapidly growing at this point in time, and there may, therefore, be significant differences in the appearances of the brains depending on the time of conception of each rat. This raises the question as to what, exactly, is a homologous section in a rat of this early age. For rats less than PND 15 or so, sagittal sections may be superior for morphometric analysis. However, even sagittal sections may be problematic if not highly homologous.

Good luck with your deliberations, Annie, and please call if there should be any questions as to how we performed this work.

Bob Bob

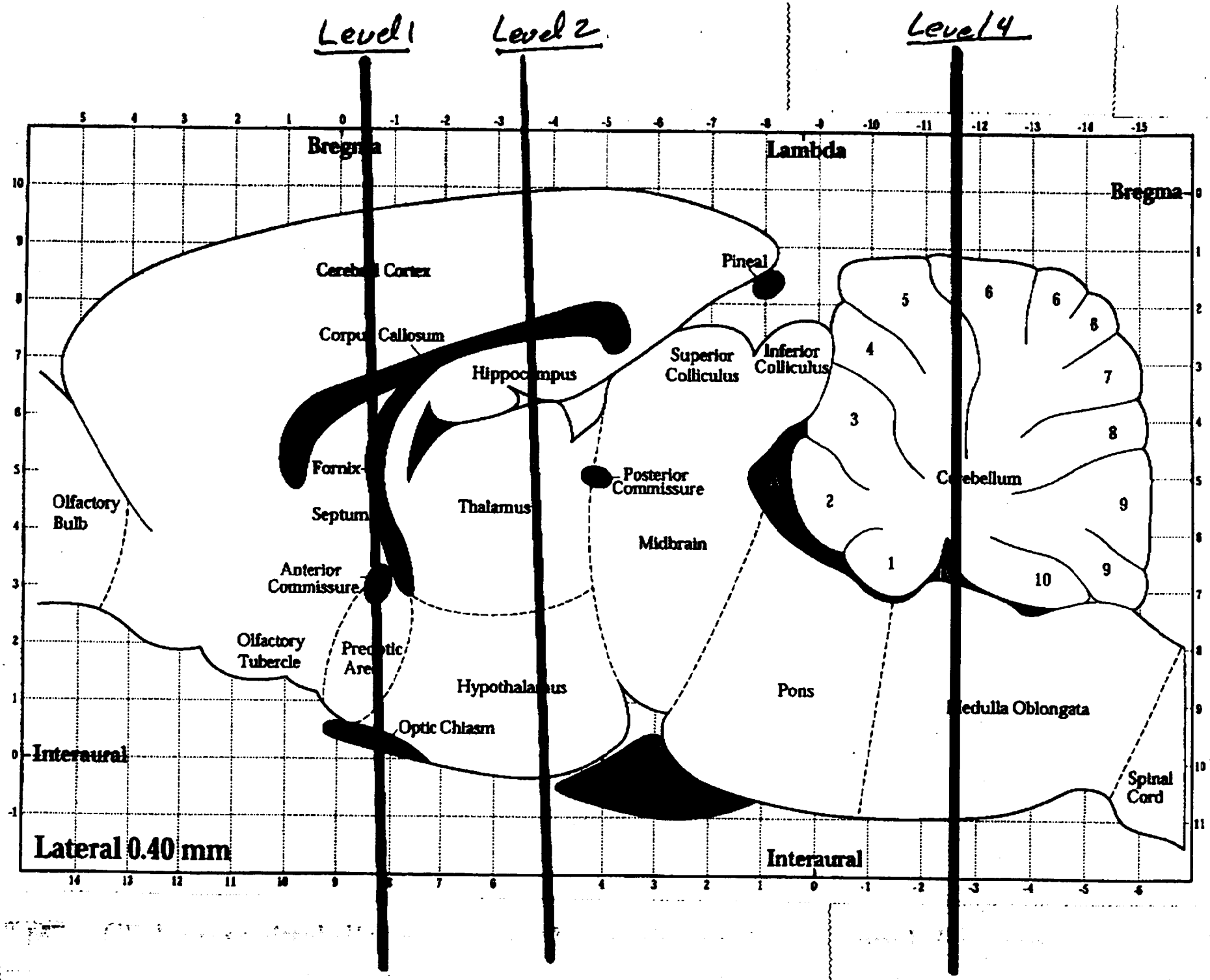
Level 1
Level 2
Level 4
Bregma
Lambda
Bregma
Cerebral Cortex
Corpus Callosum
Hippocampus
Fornix
Septum
Olfactory Bulb
Anterior Commissure
Olfactory Tubercle
Preoptic Area
Hypothalamus
Optic Chiasm
Thalamus
Posterior Commissure
Midbrain
Superior Colliculus
Inferior Colliculus
Pineal
Cerebellum
Pons
Medulla Oblongata
Spinal Cord
Interaural
Interaural
Lateral 0.40 mm
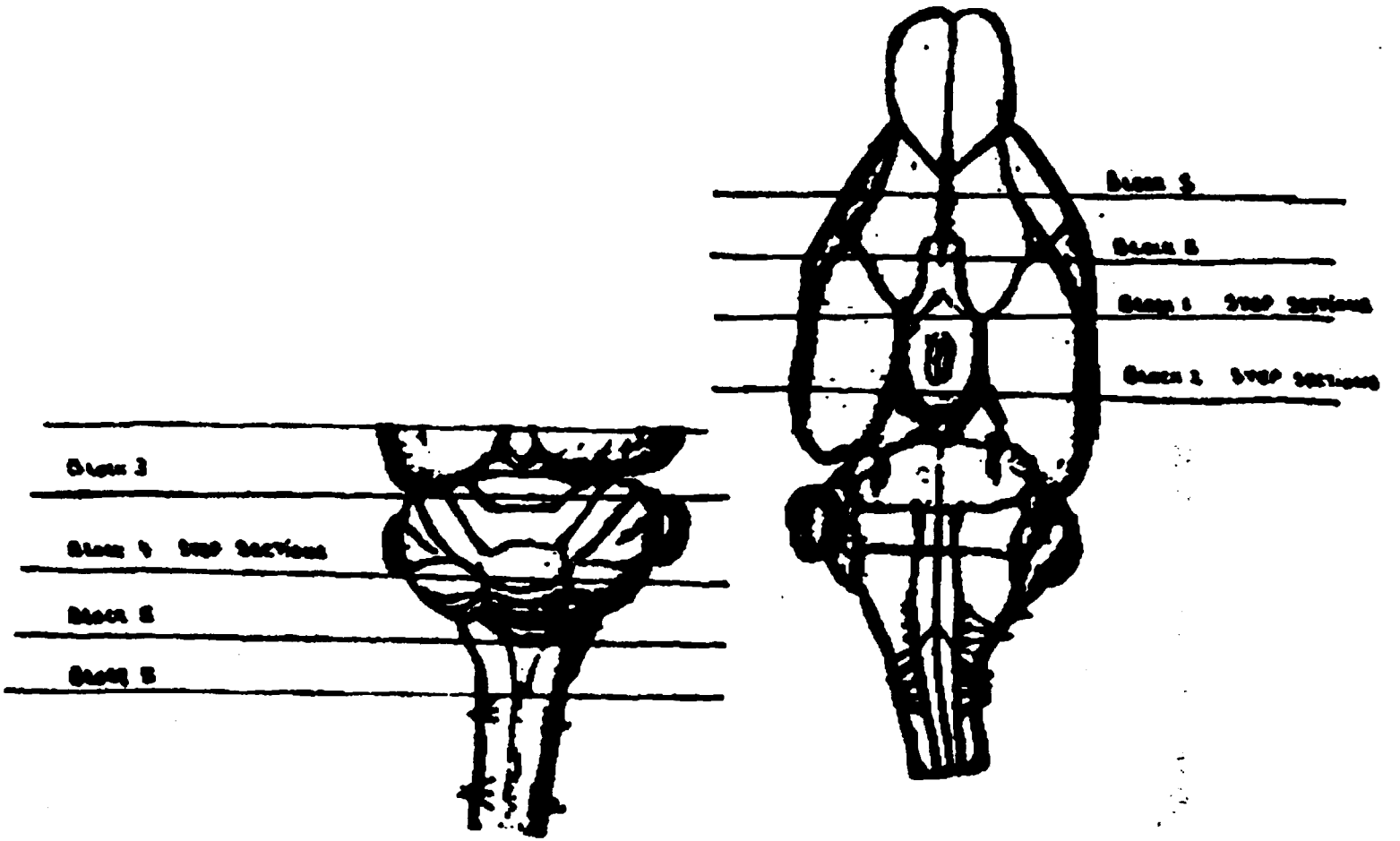
Trim Sheet for Juvenile Rat Brains Requiring Morphometry Developmental Neurotox Studies